

## **Post-Operative Instructions**

### **Shoulder Arthroscopy and SLAP Repair**

#### **Day of Surgery**

- A. Relax. Diet as tolerated.
- B. Icing is important for the first 5-7 days post-op. While the post-op dressing is in place, icing should be done continuously. Once the dressing is removed on the first or second day, ice is applied for 20-minute periods 3-4 times per day. Care must be taken with icing to avoid frostbite. Alternatively, Cryocuff or Game-ready ice cuff can be used as per instructions.

*You will be contacted by East Coast Orthotics regarding an ice compression unit to be used after surgery. This helps with pain and swelling but typically is not covered by insurance. The cost is \$200-300 for a 2-week rental. Alternatively, ice gel packs with a shoulder or knee sleeve can be provided by the hospital for a minimal charge.*

- C. Pain medication as needed every 6 hours (refer to pain medication sheet)

#### **First and Second Post-Operative Day**

- A. Continue Icing.
- B. Pain medications as needed

#### **Third Post-Operative Day**

- A. You may remove surgical bandage and shower this evening. Apply regular bandages to these wounds prior to showering and when showering is complete apply fresh regular bandages. You will need to follow this routine for 2 weeks after surgery.

#### **Physical Therapy**

- A. Physical Therapy should begin at 4 weeks. Please call your preferred facility to make an appointment.
- B. Pendulum exercises can be started on day 3.

*\*Note: Your shoulder will be very swollen. It may take a week or longer for this to go away. It is also common to notice burning around the shoulder as the swelling resolves. If excessive bleeding occurs, please notify Dr. Jazrawi.*

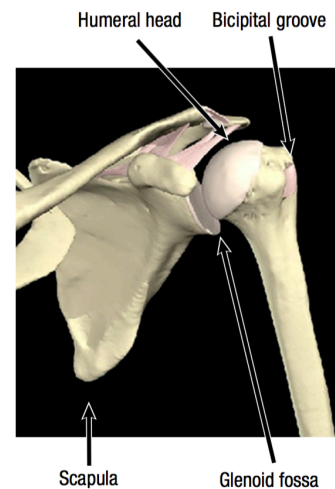
**Call our office @ 646-501-7223 option 4, option 2 to confirm your first postoperative visit, which is usually about 1-2 weeks after surgery. If you are experiencing any problems, please call our office or contact us via the internet at [www.newyorkortho.com](http://www.newyorkortho.com).**

## Dr. Laith M. Jazrawi

Chief, Division of Sports Medicine  
Associate Professor Department of Orthopaedic Surgery

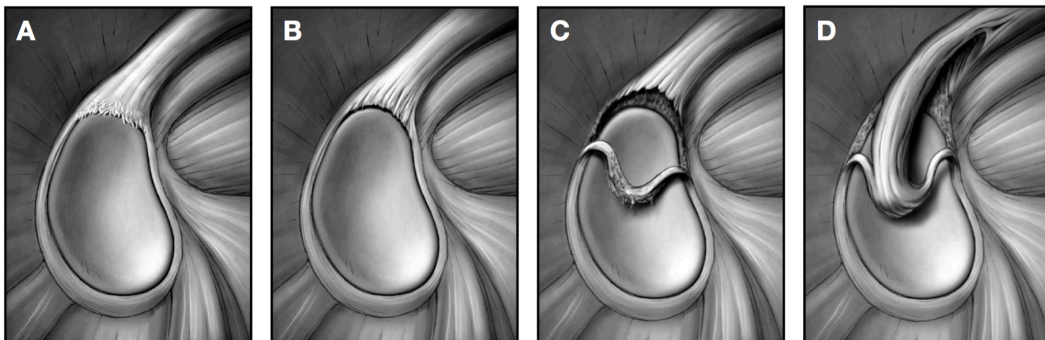
# Rehabilitation After Arthroscopic SLAP Repair

The anatomic configuration of the shoulder joint (glenohumeral joint) is often compared to a golf ball on a tee. This is because the articular surface of the round humeral head is approximately four times greater than that of the relatively flat shoulder blade face (glenoid fossa)<sup>1</sup> (Figure 1). The stability and movement of the shoulder is controlled by the rotator cuff muscles, as well as the shoulder ligaments, the capsule of the shoulder and the glenoid labrum. The labrum is a fibrocartilagenous ring which attaches to the bony rim of the glenoid fossa.<sup>1</sup> The labrum doubles the depth of the glenoid fossa to help provide stability.<sup>2</sup> An analogy would be a parked car on a hillside with a block under the tire — the round tire being the humeral head, the road being the glenoid fossa and the block being the labrum. The labrum also serves as the anchor for the long head of the biceps. A large portion of the long head of the biceps originates from the top (superior) portion of the labrum. Overhead sports can create significant forces at this attachment site. This can ultimately lead to injury and tears of the biceps off this attachment. This is called a SLAP lesion (Superior Labral Anterior to Posterior tear). These injuries can also occur from trauma, such as falling on your arm, bracing your arm in an accident, arm tackling in football or any large sudden force applied to the arm. There are four basic types of SLAP tears.<sup>3</sup> A Type II SLAP tear is the most common type of SLAP tear requiring surgical reconstruction (Figure 2).<sup>3</sup> In this type of tear the long head of the biceps remains attached to the labrum but the labrum has been detached from the



**Figure 1** Anatomical configuration of the shoulder joint (glenohumeral joint)

Reprinted with permission from Primal Pictures, Ltd. (primalpictures.com). Unauthorized use of this image is prohibited.



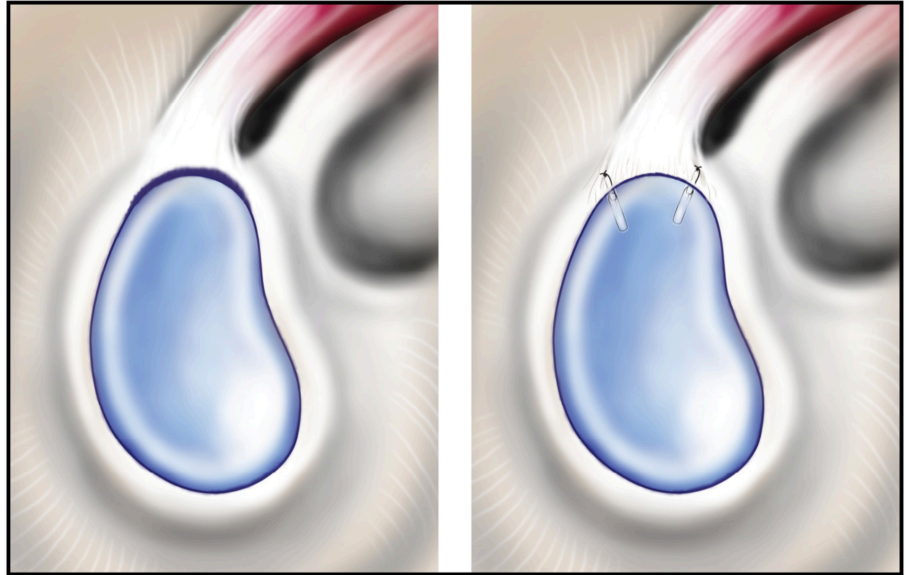
**Figures 2-A through 2-D** The classification system for SLAP lesions. **Figure 2-A** A Type-I SLAP lesion consists of degenerative fraying on the inner margin of the superior aspect of the labrum. **Figure 2-B** With a Type-II SLAP lesion, the biceps attachment and the adjacent superior aspect of the labrum have pulled off the superior glenoid tubercle. **Figure 2-C** A Type-III SLAP lesion is a superior labral bucket-handle tear that extends into the biceps tendon. **Figure 2-D** A Type IV

Reprint permission for illustrations and photos is granted by The Journal of Bone and Joint Surgery, Inc. The copyright is owned by The Journal of Bone and Joint Surgery, Inc.

## Rehabilitation After Arthroscopic SLAP Repair

bony glenoid.<sup>4</sup> This is repaired surgically by placing suture anchors (Figure 3) in the glenoid fossa, passing sutures through the labrum and then tying special surgical knots to approximate the labrum back to the bony glenoid rim.

Full return to throwing and contact sports occurs in 80-90% of athletes.<sup>4, 5</sup> Successful return to sport and activity is dependent on following post-operative precautions and completing a structured post-operative rehabilitation program. Our rehabilitation program is outlined below. The rehabilitation guidelines are presented in a criterion based progression. General time frames are given for reference to the average, but individual patients will progress at different rates depending on their age, associated injuries, pre-injury health status, rehabilitation compliance and injury severity. These factors will also affect how long it takes each individual to meet the required criteria for return to sport and activity.<sup>4</sup>



**Figure 3.** The first illustration shows a Type II SLAP tear extending from 10:00 to 2:00. The second illustration shows this tear repaired with sutures and anchors anterior to and posterior to the long head of the biceps. The number of suture anchors needed varies from case to case.

## Rehabilitation After Arthroscopic SLAP Repair

### Phase I (Surgery to 4 weeks after surgery)

Goals	<ul style="list-style-type: none"><li>○ Protection of shoulder after surgery</li><li>○ Activate muscles that help stabilize your glenohumeral and scapulo-thoracic joints</li></ul>
Precautions	<ul style="list-style-type: none"><li>○ Sling immobilization at all times except for showering and rehabilitation under guidance of physical therapist</li></ul>
Range of Motion Exercises	<ul style="list-style-type: none"><li>○ Active assistive range of motion (AAROM) → active range of motion (AROM)</li><li>○ Restrict motion to 140° of Forward Flexion, 40° of External Rotation and Internal Rotation to stomach</li><li>○ No Internal Rotation up the back</li><li>○ No External Rotation behind the head</li></ul>
Therapeutic Exercises	<ul style="list-style-type: none"><li>○ Wrist/Hand Range of Motion</li><li>○ Grip Strengthening</li><li>○ Isometric Abduction, Internal/External Rotation exercises with elbow at side</li><li>○ No resisted Forward Flexion/Elbow Flexion (to avoid stressing the biceps origin)</li></ul>
Other Suggestions	<ul style="list-style-type: none"><li>○ Heat/Ice before and after PT sessions</li></ul>

### Phase II (4 weeks to 6 weeks following surgery)

Goals	<ul style="list-style-type: none"><li>○ Increased AROM</li><li>○ Increased rotator cuff strength in a neutral position</li></ul>
Precautions	<ul style="list-style-type: none"><li>○ Discontinue sling immobilization</li></ul>
Range of Motion Exercises	<ul style="list-style-type: none"><li>○ Increase Forward Flexion, Internal/External Rotation to full motion as tolerated</li></ul>
Therapeutic Exercises	<ul style="list-style-type: none"><li>○ Advance isometrics from Phase I to use of a theraband within AROM limitations</li><li>○ Continue with Wrist/Hand Range of Motion and Grip Strengthening</li><li>○ Begin Prone Extensions and Scapular Stabilizing Exercises (traps/rhomboids/levator scapula)</li><li>○ Gentle joint mobilization</li></ul>
Other Suggestions	<ul style="list-style-type: none"><li>○ Modalities per PT discretion</li></ul>

## Rehabilitation After Arthroscopic SLAP Repair

### Phase III (6 weeks to 12 weeks following surgery)

Goals	<ul style="list-style-type: none"><li>○ Progress to full AROM without discomfort</li></ul>
Range of Motion Exercises	<ul style="list-style-type: none"><li>○ Active assistive range of motion (AAROM) → active range of motion (AROM)</li><li>○ Restrict motion to 140° of Forward Flexion, 40° of External Rotation and Internal Rotation to stomach</li><li>○ No Internal Rotation up the back</li><li>○ No External Rotation behind the head</li></ul>
Therapeutic Exercises	<ul style="list-style-type: none"><li>○ Advance Theraband exercises to light weights (1-5 lbs)</li><li>○ 8-12 repetitions/2-3 sets for Rotator Cuff, Deltoid and Scapular Stabilizers</li><li>○ Continue and progress with Phase II exercises</li><li>○ Begin UE ergometer</li></ul>
Other Suggestions	<ul style="list-style-type: none"><li>○ Modalities per PT discretion</li></ul>

### Phase IV (3 months to 6 months following surgery)

Goals	<ul style="list-style-type: none"><li>○ Full range of motion without discomfort</li></ul>
Therapeutic Exercises	<ul style="list-style-type: none"><li>○ Advance exercises in Phase III (strengthening 3x per week)</li><li>○ Sport/Work specific rehabilitation</li><li>○ Return to throwing at 4.5 months</li><li>○ Return to sports at 6 months if approved</li></ul>
Other Suggestions	<ul style="list-style-type: none"><li>○ Modalities per PT discretion</li></ul>

## References

1. Wilk KE, Reinold MM, Dugas JR, Arrigo CA, Moser MW, Andrews JR. Current concepts in the recognition and treatment of superior labral (SLAP) lesions. *J Orthop Sports Phys Ther.* May 2005;35(5):273-291.
2. Perry J. Anatomy and biomechanics of the shoulder in throwing, swimming, gymnastics, and tennis. *Clin Sports Med.* Jul 1983;2(2):247-270.
3. Barber A, Field LD, Ryu R. Biceps tendon and superior labrum injuries: decision-marking. *J Bone Joint Surg Am.* Aug 2007;89(8):1844-1855.
4. Park HB, Lin SK, Yokota A, McFarland EG. Return to play for rotator cuff injuries and superior labrum anterior posterior (SLAP) lesions. *Clin Sports Med.* Jul 2004;23(3):321-334, vii.
5. Funk L, Snow M. SLAP tears of the glenoid labrum in contact athletes. *Clin J Sport Med.* Jan 2007;17(1):1-4.



## Rehabilitation Protocol: Arthroscopic SLAP Repair

Name: \_\_\_\_\_

Date: \_\_\_\_\_

Diagnosis: \_\_\_\_\_

Date of Surgery: \_\_\_\_\_

☐ **Phase I (Weeks 0-4)**

- Sling immobilization at all times except for showering and rehab under guidance of PT
- Range of Motion – AAROM → AROM as tolerated
  - Restrict motion to 140° of Forward Flexion, 40° of External Rotation and Internal Rotation to stomach
  - No Internal Rotation up the back/No External Rotation behind the head
- Therapeutic Exercise
  - Wrist/Hand Range of Motion
  - Grip Strengthening
  - Isometric Abduction, Internal/External Rotation exercises with elbow at side
  - No resisted Forward Flexion/Elbow Flexion (to avoid stressing the biceps origin)
- Heat/Ice before and after PT sessions

☐ **Phase II (Weeks 4-6)**

- Discontinue sling immobilization
- Range of Motion – Increase Forward Flexion, Internal/External Rotation to full motion as tolerated
- Therapeutic Exercise
  - Advance isometrics from Phase I to use of a theraband within AROM limitations
  - Continue with Wrist/Hand Range of Motion and Grip Strengthening
  - Begin Prone Extensions and Scapular Stabilizing Exercises (traps/rhomboids/levator scapula)
  - Gentle joint mobilization
- Modalities per PT discretion

☐ **Phase III (Weeks 6-12)**

- Range of Motion – Progress to full AROM without discomfort
- Therapeutic Exercise – Advance theraband exercises to light weights (1-5 lbs)
  - 8-12 repetitions/2-3 sets for Rotator Cuff, Deltoid and Scapular Stabilizers
  - Continue and progress with Phase II exercises
  - Begin UE ergometer
- Modalities per PT discretion

☐ **Phase IV (Months 3-6)**

- Range of Motion – Full without discomfort
- Therapeutic Exercise – Advance exercises in Phase III (strengthening 3x per week)
  - Sport/Work specific rehabilitation
  - Return to throwing at 4.5 months
  - Return to sports at 6 months if approved
- Modalities per PT discretion

**Comments:****Frequency:** \_\_\_\_\_ **times per week****Duration:** \_\_\_\_\_ **weeks****Signature:** \_\_\_\_\_**Date:** \_\_\_\_\_